



Breast Tomosynthesis

The Use of Breast Tomosynthesis in a Clinical Setting

What's Inside

Introduction	1
Clinical Performance of Hologic Breast Tomosynthesis	1
Improved Sensitivity and Reduced Recalls	2
Greater Performance Using Two-View Tomosynthesis	2
Performance of Tomosynthesis in Different Breast Compositions and Lesion Types	3
Performance in Calcifications, Masses and Distortions	3
Performance in Invasive and Noninvasive Cancers	4
Performance in Fatty and Dense Breasts	4
Tomosynthesis Compared to Ultrasound	5
Tomosynthesis Performance in the Evaluation of Symptomatic Patients	5
Clinical Considerations in Implementing Tomosynthesis	6
One-View Versus Two-View Tomosynthesis	6
Benefits of Having Both Tomosynthesis and 2D Images in All Views	7
Patient Selection and Management	8
Use of Tomosynthesis for Screening or Diagnostic Imaging	8
Use of Tomosynthesis for Women with Dense Breasts	8
Reducing Patient Dose in Tomosynthesis	8
Tomosynthesis Reading Time	9
Advances in Tomosynthesis	9
Tomosynthesis-Guided Biopsy	9
Contrast Enhanced Breast Imaging	10
Conclusions	11
Glossary	11
References	12

Breast Tomosynthesis

The Use of Breast Tomosynthesis in a Clinical Setting

Andrew Smith, Ph.D., Vice President - Imaging Science, Hologic

Introduction

Since the United States (US) Food and Drug Administration's (FDA) approval of the first commercial systems in 2000, digital mammography has become an accepted standard of care in breast cancer screening and diagnosis and has paved the way for the newest groundbreaking technology in this arena - breast tomosynthesis, also referred to as 3D mammography - or simply "tomo."

Breast tomosynthesis is a screening and diagnostic modality that acquires images of a breast at multiple angles during a short scan. The individual images are then reconstructed into a series of thin, high-resolution slices typically 1 mm thick, which can be displayed individually or in a dynamic ciné mode.

A tomosynthesis dataset greatly reduces detection challenges associated with overlapping structures in the breast, which is the primary drawback of conventional 2D analog and digital mammography. In clinical use, Hologic breast tomosynthesis offers significant benefits including increased cancer detection, decreased callback rates, help in localizing structures in the breast, and improved lesion and margin visibility.

Tomosynthesis has been available in Europe and other countries recognizing the CE mark since 2008. In February 2011, the Hologic Selenia® Dimensions® breast tomosynthesis system was the first commercial system approved by the US FDA. The system is approved for use in the same clinical indications as 2D mammography, including breast cancer screening, diagnosis, and intervention. With the Hologic tomosynthesis system, a combined examination of tomo and 2D, known as combo mode, takes only seconds longer than a conventional two dimensional digital mammogram. In 2013 the US FDA approved a new mode for the Hologic system, whereby the 2D image is generated from the tomosynthesis dataset directly (C-View™ 2D image), avoiding the need for a

separate 2D exposure and essentially halving the radiation dose associated with a tomosynthesis procedure.

This white paper provides detailed information about the performance of Hologic's tomosynthesis technology now that it has been evaluated in large scale screening trials and is in routine clinical use. It also looks at the performance of tomosynthesis in different breast composition and lesion types, discusses a number of issues to consider when introducing tomosynthesis into clinical practice, and provides a summary of some of the advanced applications for this modality.

Clinical Performance of Hologic Breast Tomosynthesis

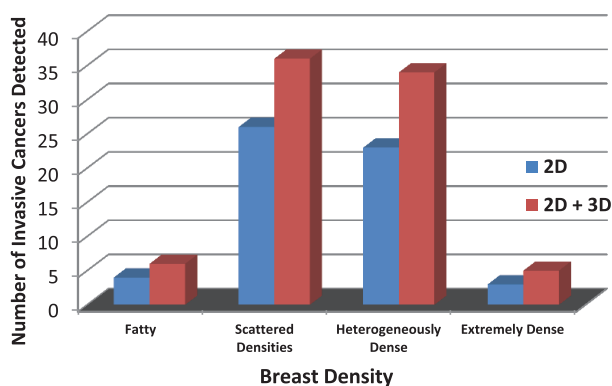
The performance of tomosynthesis has been evaluated in a number of venues, including the clinical trials in support of the US FDA submissions, and more recently, in Europe in large screening trials and in US sites that monitored performance before and after the introduction of tomosynthesis into routine clinical practice.

Hologic conducted a large multi-center clinical trial comparing the performance of 2D digital mammography plus tomo imaging (combo mode) to that of 2D mammography alone in support of its FDA tomosynthesis submission.¹ This study found that the addition of tomosynthesis to digital mammography both significantly increased diagnostic accuracy and significantly reduced recall rates for non-cancer cases. These results were consistent with those of an independent reader study where University of Pittsburgh researchers found a 7% improvement in the area under the receiver operating characteristics (ROC) curve for 2D plus tomo compared to 2D alone.² The FDA advisory panel considered all three reader studies and voted that Hologic's clinical data demonstrated both the effectiveness and safety of tomosynthesis.

Improved Sensitivity and Reduced Recalls

The performance of breast tomosynthesis has been evaluated in a large screening trial from Oslo Norway. Results have been presented from the first three months and the first year of the 2-year trial.³⁻⁵ In the 1-year evaluation of 12,631 screening examinations, where participants were imaged with both digital mammography and tomosynthesis, the researchers reported that the detection rate for invasive cancers increased 40%, the overall cancer detection rate increased 27% and the false positive rates decreased by 15% for examinations employing tomosynthesis compared to mammography alone. These results were seen across all breast densities. Summarizing the results of the Oslo trial gives the following results for the performance of tomosynthesis:

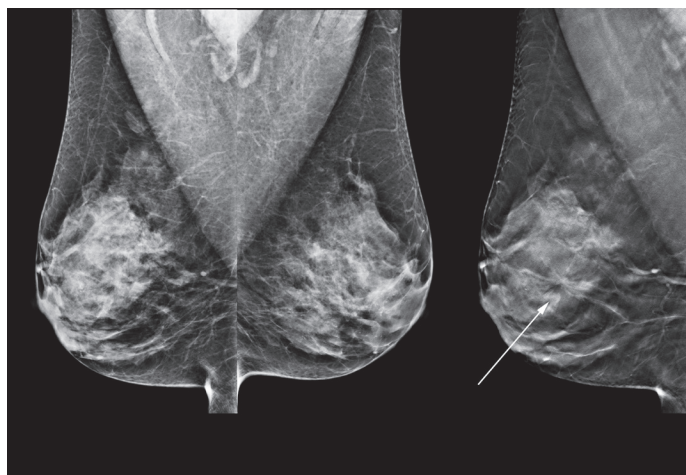
- Invasive cancer detection increased 40%
- Cancer detection increased 27%
- False positives decreased 15%



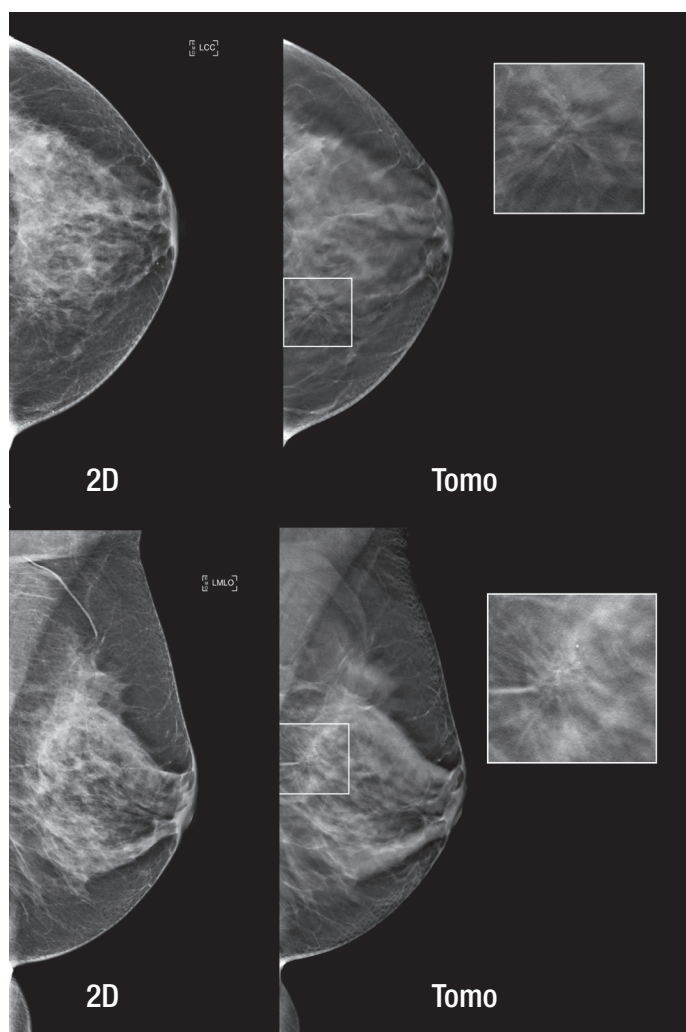
The study by Skaane showed improvements in invasive cancer detection in all breast density categories.

Another large population-based screening trial of tomosynthesis conducted in Italy involved over 7,000 women and reported a 51% increase in cancer detection with the use of tomosynthesis.⁶

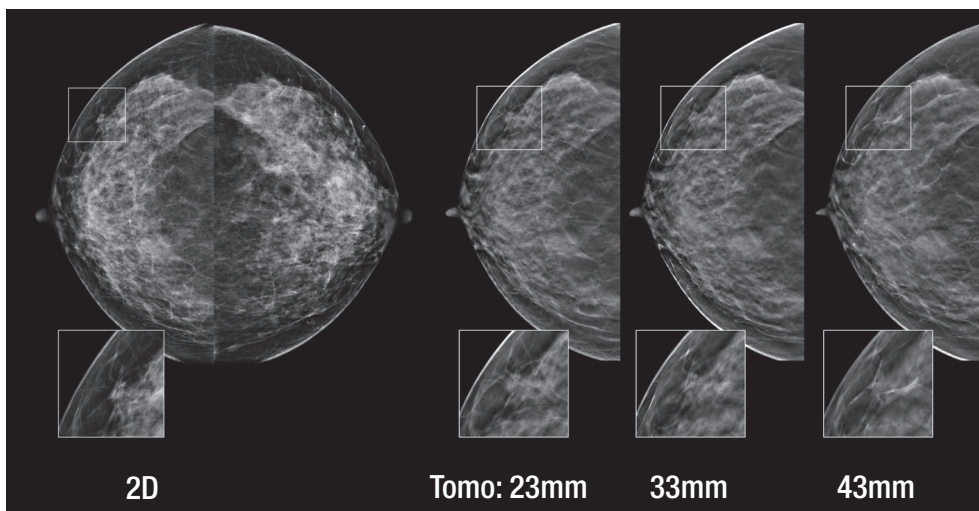
The performance of tomosynthesis in routine screening practice has also been evaluated in observational studies, where the changes in performance measures with and without the use of tomosynthesis in clinical practice were reported.^{7,8,9} The reported metrics vary in these studies, with an overall average cancer detection rate increase of 22% and an average recall rate reduction of 28%. The Rose study specifically called out the invasive cancer detection rate, which showed an increase of 54% with the use of tomosynthesis.¹⁰



INCREASED CANCER DETECTION: The tomosynthesis reconstructed slice shown on the right reveals a definitive spiculated mass that is only faintly revealed in the 2D image shown on the left. (Diagnosis: Invasive Ductal Carcinoma)



OCCULT IN 2D: The architectural distortion in this breast, while essentially occult in the 2D mammograms, is easily visualized in the tomosynthesis images.



REDUCED RECALL RATES: The 2D mammogram reveals what appears to be a spiculated mass laterally in the right CC view. Tomosynthesis slices at 23, 33, and 43 mm above the breast platform show that this 2D finding was superimposed structures, resolved through the use of tomosynthesis imaging.

Greater Performance Using Two-View Tomosynthesis

All of the above referenced clinical studies used two-view mammography for both 2D and tomosynthesis imaging. As part of the study submitted to the US FDA another arm was investigated: single-view tomosynthesis (MLO) imaging in combination with two-view (CC and MLO) 2D imaging. In this study, the performance of 2D imaging plus tomo MLO showed that the tomo MLO-only arm performed better than 2D imaging alone, but not as well as 2D plus both tomo views.

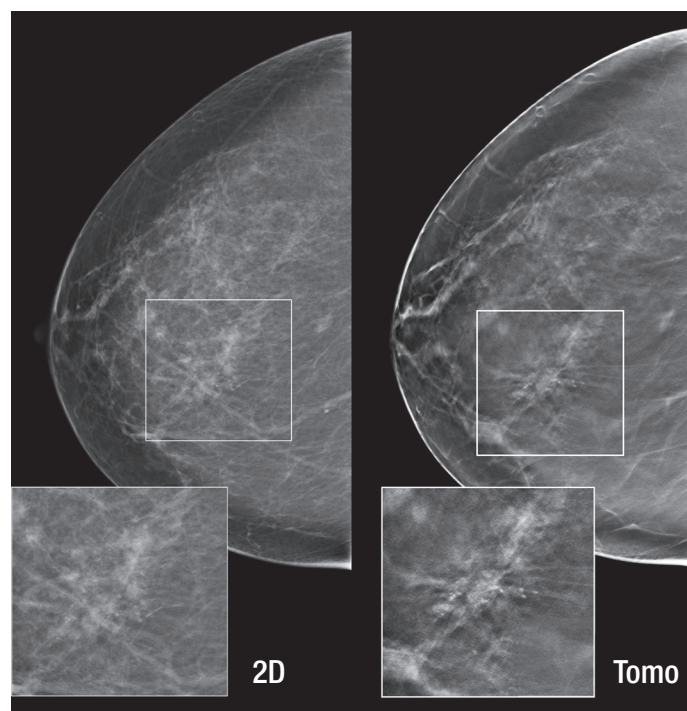
These results are consistent with other studies, illustrating that MLO-only tomosynthesis is likely to be inferior to two-view tomo. These study results are explored in greater detail in the discussion of one-view versus two-view tomosynthesis later in this paper.

Performance of Tomosynthesis in Different Breast Compositions and Lesion Types

The expanding library of clinical trial results on the use of tomosynthesis makes it possible to evaluate its performance in different breast compositions and lesion types such as calcifications, masses and distortions, invasive and noninvasive cancers, and fatty and dense breast tissue. There are also some study results demonstrating how the use of tomosynthesis may affect the management of symptomatic patients.

Performance in Calcifications, Masses and Distortions

The clinical trial data presented as part of Hologic's FDA submission has been analyzed by separating the image sets into calcification and non-calcifications cases. Rafferty found that 2D plus tomo offered a very significant increase in performance relative to 2D imaging for cases involving masses and distortions. For cases involving microcalcifications, there was a small, but not statistically significant, improvement in the ROC performance with the addition of tomosynthesis.



ADDED VALUE FOR CALCIFICATIONS: The 2D mammogram on the left shows right medial microcalcifications. The tomosynthesis reconstructed slice on the right illustrates the associated architectural distortion only revealed on the CC tomosynthesis image and not on the mammogram. (Diagnosis: Ductal Carcinoma In-situ/High Grade)

Performance in Invasive and Noninvasive Cancers

From the FDA studies it could be predicted that the majority of additional cancers found by tomosynthesis will be mass lesions and not calcification-only cancers because of the much greater improvement in the ROC curve performance in the reader studies for non-calcifications than for cases involving calcifications. Thus, it is to be expected that the gain in sensitivity using tomosynthesis can be primarily attributable to invasive cancers. Recent results reporting the performance of tomosynthesis in screening are showing exactly this. Skaane⁴ reported a 40% increase in the detection of invasive cancers using tomosynthesis, with no increase in the detection of ductal carcinoma in situ (DCIS). Similarly, Rose¹⁰ reported a 53% increase in invasive cancer detection using tomosynthesis, and as with Skaane, no increase in the detection of non-invasive cancers. Ciatto also showed an increase in cancer detection of about 50%, and no increase in the detection of in-situ cancers.⁶

This represents one of the key benefits of tomosynthesis; the potential for earlier detection of invasive cancers – exactly the cancers that will advance to become life-threatening if not detected in time for effective treatment. These tomo-only cancers represent cancers that were missed in 2D imaging and would not have been found until a successive screening round one or more years out or when the mass became palpable, had the tomo scan not been performed.

Performance in Fatty and Dense Breasts

Tomosynthesis has been shown to improve the performance of mammography in both fatty and dense breasts. Because denser breasts have more structure noise (fibroglandular tissue) than fatty breasts, it was expected that tomosynthesis would improve the performance of mammography in the denser breasts, however clinical data shows that tomosynthesis helps across the spectrum of breast densities.

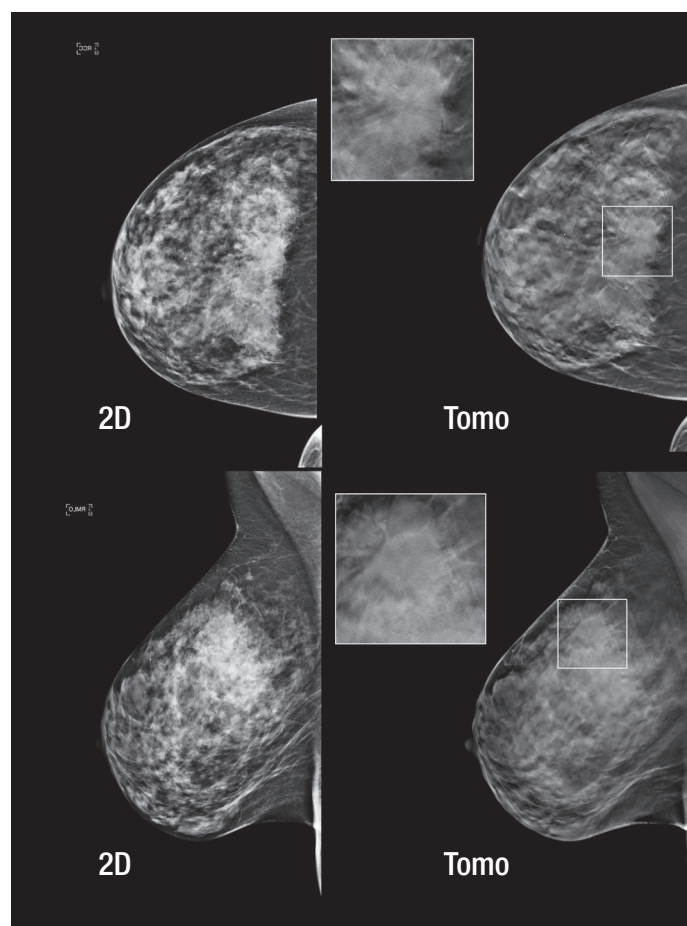
This was reported in the paper by Haas et al.⁷ This study looked at the performance of tomosynthesis in 13,000 women undergoing breast cancer screening. They found that the addition of tomosynthesis reduced recall rates for all breast density groups, with statistically significant reductions in recall rate for scattered fibroglandular (reduction of 25%), heterogeneously dense (reduction of 39%), and extremely dense breasts (reduction of 57%).

Other researchers have reported similar trends. Rafferty studied the performance of tomosynthesis in women with dense breasts and found an increase in the recall for cancer cases and a reduction in the recall rate for non-cancer cases.¹¹ In a separate study, Rafferty found that 2D plus tomo was significantly better than 2D mammography alone

in ROC performance for both fatty and dense breasts.¹² While there was a gain in the area under the ROC curve in both breast density types, the gain was 2-3 times higher in dense breasts than it was in fatty breasts. Rafferty also reported large recall rate reductions in both fatty and dense breast types.

Philpotts et al. reports on tomosynthesis visualization of breast cancers as a function of mammography density.¹³ They found that tomosynthesis was particularly beneficial for visualizing non-calcified breast cancers in scattered and heterogeneously dense breasts, with about 70% of cancers in these density categories seen only or better with tomosynthesis. Patients with fatty and extremely dense breasts had cancers seen equally well using tomosynthesis and 2D mammography.

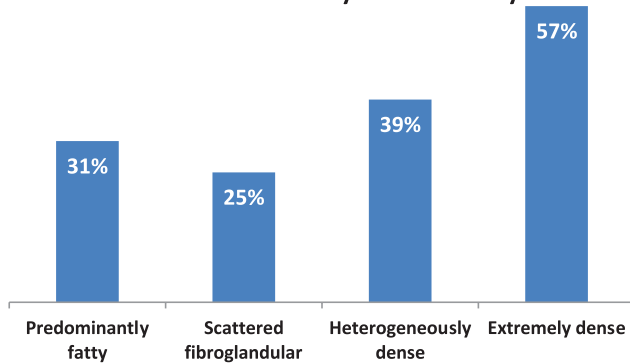
In terms of the detection of invasive lobular carcinoma (ILC), Gandini has reported that the detection of ILC was significantly higher using tomosynthesis than digital mammography, especially in dense breasts.¹⁴ Radiologists were twice as likely to miss an ILC in dense breasts using digital mammography than when using tomosynthesis.



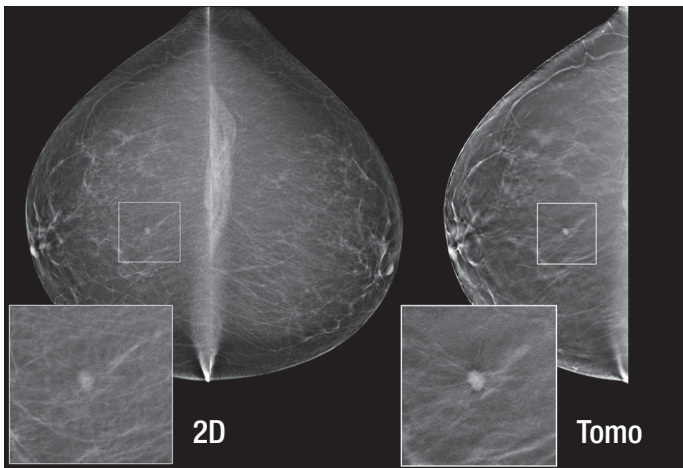
TOMOSYNTHESIS IN DENSE BREASTS: The cancer in this dense breast is much better visualized in the tomosynthesis images than in the 2D mammograms. (Diagnosis: Signet Ring Cell Carcinoma).

These results are as expected. Fatty breasts often have sufficient parenchyma that tomosynthesis would be expected to offer some advantages. However, the even larger improvement in performance in denser breasts using tomosynthesis illustrates that tomosynthesis is doing what is expected from the physics principles – reducing superimposed parenchyma.

Recall Rate Reduction by Breast Density



In the study by Haas, et al., the addition of tomosynthesis decreased recalls across all breast densities, with significant reductions in denser breasts.



VALUE IN FATTY BREASTS: While the 2D mammogram reveals the 12:00 o'clock mass, tomosynthesis more accurately characterizes this mass as spiculated (Invasive Ductal Carcinoma).

Tomosynthesis Compared to Ultrasound

No studies have been published directly comparing the performance of tomosynthesis to ultrasound in breast cancer screening. Nonetheless, several observations may be made about this. Tomosynthesis, like ultrasound, has a superior performance in dense breasts relative to mammography. However, unlike ultrasound, where the recall rate of 2D and ultrasound was 4 times that of 2D mammography alone as was seen in the ACRIN 6666 trial, tomosynthesis improves sensitivity without increasing the recall rate.^{15,4,10} Further clinical research will be needed to identify the respective roles of tomosynthesis and ultrasound, particularly in

screening women with the very densest breasts, but it is clear that tomosynthesis can offer improved cancer detection in dense breasts while simultaneously reducing false positives.

Tomosynthesis Performance in the Evaluation of Symptomatic Patients

The use of tomosynthesis in diagnostic assessment offers the opportunity for both improved performance and a reduction in the number of x-ray images needed, with a resultant reduction in both dose and exam time.

Zuley et al. found that two-view tomosynthesis significantly improved diagnostic accuracy for non-calcified lesions compared to supplemental mammographic views.¹⁶ All 8 radiologists participating in the study showed improved performance. Because the number of diagnostic views in the evaluation of masses or focal asymmetries can average three or more¹⁷, there is a clear opportunity to reduce radiation exposure through the use of tomosynthesis in diagnostic evaluations.

Butler et al. had similar conclusions, and reported that tomosynthesis results in decreased number of images required for diagnostic cases.¹⁸ They further concluded that this expedites the work up and yields better patient throughput.

Other researchers such as Svahn have also shown that the combined diagnostic performance of digital mammography and tomosynthesis is superior to either digital mammography or tomosynthesis alone.¹⁹

Several studies have shown that tomosynthesis is superior to 2D mammography in predicting tumor size, demonstrating margins, extents of lesions, and in staging:

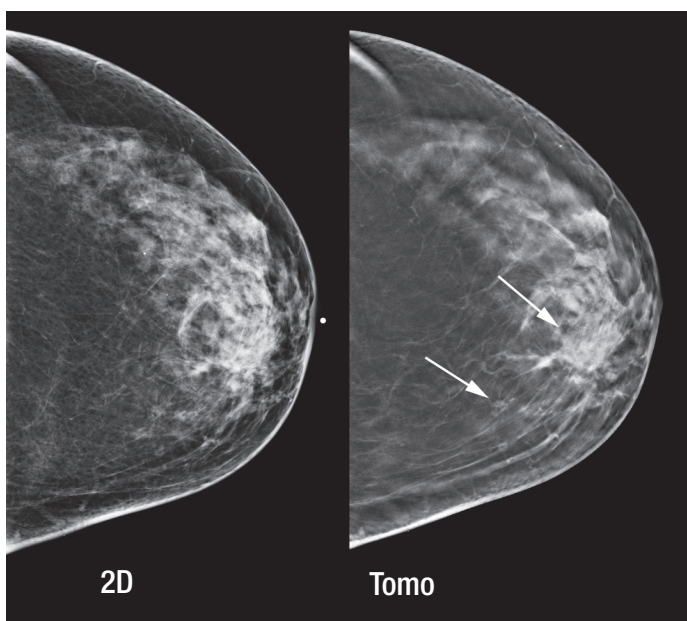
Moon showed that adding tomosynthesis to digital mammography increased cancer detection and diagnostic performance in diagnostic workup.²⁰

Michell showed that tomosynthesis is superior to 2D mammography in predicting the histological tumor size because tomosynthesis demonstrates the margins and extents of the mammographic lesions more clearly. His study concluded that this modality provided critical information for prospective treatment planning by the multi-disciplinary team.²¹

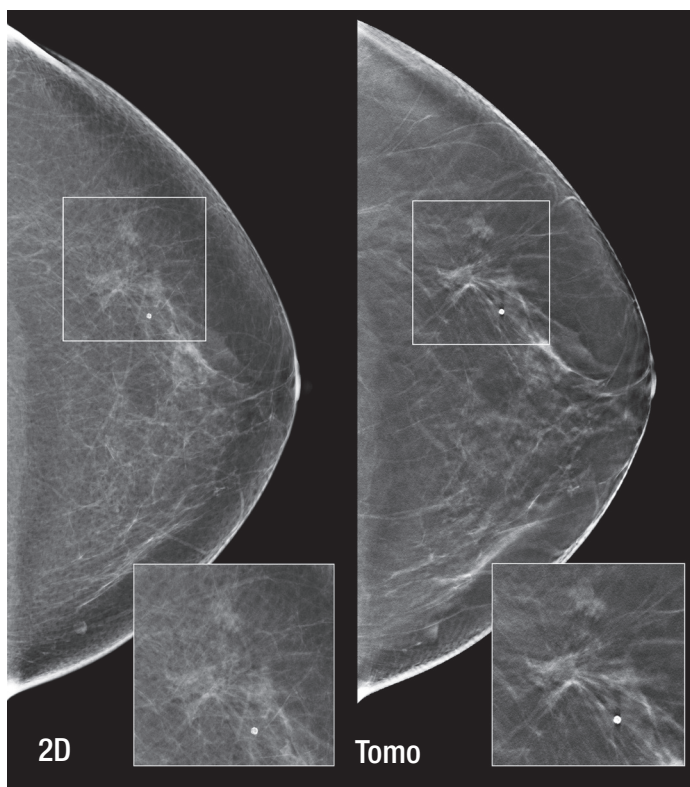
Fornvik found breast tomosynthesis superior to digital mammography in the assessment of breast tumor size and stage.²²

Meacock found that tomosynthesis was more accurate than 2D in tumor size measurement.²³

Tagliafico found that tomosynthesis could replace spot compression views, lowering both radiation dose and offering the potential to reduce biopsies on non-malignant lesions.²⁴



GREATER PERCEPTION OF EXTENT OF DISEASE: In addition to the subtle area of architectural distortion best defined on the tomosynthesis reconstructed slice on the right (top arrow), a second spiculated mass is also revealed (bottom arrow) 21 mm posterior to the primary area of interest. (Diagnosis for both areas: Invasive Ductal Carcinoma)



REDUCED NEED FOR WORK-UP: Tomosynthesis demonstrates a definitive architectural distortion only subtly appreciated on the 2D digital mammogram, replacing the need for a diagnostic work-up that may not fully or accurately resolve the 2D imaging dilemma.

Clinical Considerations in Implementing Tomosynthesis

Clinical research has shown the benefits of tomosynthesis in screening and diagnostic indications, as well as in a range of breast compositions and tissue types. However, there are a number of clinical considerations to be evaluated when determining how to introduce tomosynthesis to a clinical practice. What configuration of 2D and tomosynthesis views ensures the earliest possible detection of breast cancers and reduction of unnecessary recalls? How will these choices affect patient dose? How should patients be managed in a mixed 2D and tomosynthesis environment?

These considerations are discussed in more detail below.

One-View Versus Two-View Tomosynthesis

The relative performance of one-view versus two-view 2D mammography is well understood. Screening using two views offers an increase in cancer detection and a reduction in recall rate compared to single-view mammography; the paper by Wald estimates the sensitivity gain is 24% and recall rate reduction is 15%.²⁵

Equivalently, single-view tomosynthesis (either CC or MLO) is a lower-dose procedure compared to two-view tomosynthesis, but it has been demonstrated to have poorer clinical performance. There is considerable evidence that two-view tomosynthesis has increased sensitivity relative to one-view tomosynthesis. This has been illustrated in the initial Hologic reader studies, where the clinical performance of two-view 2D combined with a single (MLO) tomosynthesis view was inferior to the performance of two-view 2D combined with two-view tomo imaging.

Other data supports this finding:

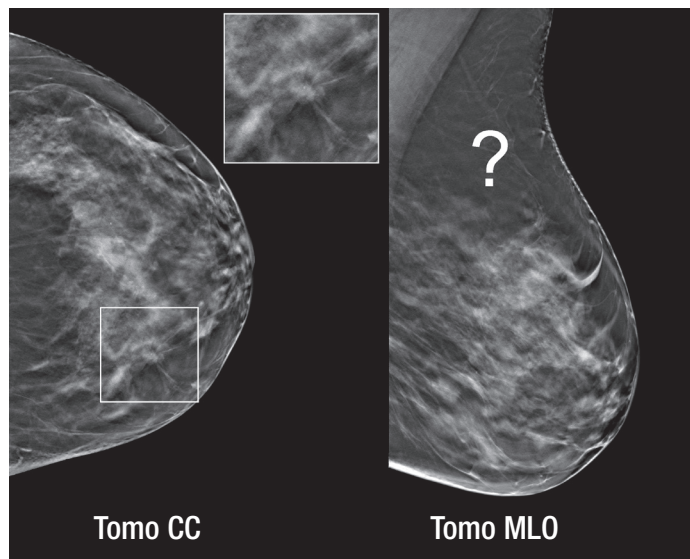
Rafferty found that 12% of lesions were better seen on the tomosynthesis MLO image, 15% better seen on tomo CC and 9% of lesions were visible only on tomo CC.²⁶

Beck found that only about half of lesions were equally well seen on both the MLO and CC view, with 34% of cancers better or only seen on the CC view.²⁷ 7% of lesions were only seen on one view. The authors emphasized the importance of including the CC view in breast tomosynthesis and concluded that obtaining both views is necessary to ensure that a cancer will be optimally visualized and derive the greatest potential benefit from tomosynthesis.

Similar results were reported by Baker, who found 8% of lesions were visible only on the tomosynthesis CC view and 1.4% only on the tomo MLO.²⁸

These results are also consistent with evaluations where studies comparing the ROC performance of two tomosynthesis views demonstrate superior performance over two-view digital mammography (Michell), but studies comparing one-view tomo to two-view digital mammography have poorer performance and do not show superiority (Gennaro, Wallis).^{29,30,31}

No study using single-view tomosynthesis has demonstrated an improvement in screening cancer detection rates over digital mammography.



TWO-VIEW TOMOSYNTHESIS OPTIMIZES CHANCE FOR CANCER DETECTION: A lesion can be seen in the tomosynthesis CC view but it is not apparent in any of the tomosynthesis MLO slices. (The central MLO slice is shown above.) A number of researchers have concluded that two-view tomosynthesis improves radiologist performance over single view tomosynthesis.

In addition to the likely loss of sensitivity that occurs if only one tomo view is taken, there are some clinical challenges that arise with single view tomosynthesis imaging. Neither the CC nor the MLO views always captures all the breast tissue, so both views in some form are needed.

Mixing technologies, such as combining a tomosynthesis MLO view and a 2D mammography CC image, might address the tissue coverage, but creates its own set of issues. It might be difficult, for example, to correlate a suspicious lesion seen in 2D CC with the same lesion in the tomo MLO, or vice versa. The approach of a tomosynthesis MLO and a 2D CC is likely inferior in clinical performance to performing tomosynthesis in both the MLO and CC view – and offers no dose advantage. The reason for this is clear. Just as some cancers in the MLO view are better appreciated in tomosynthesis than in a 2D MLO image, some cancers in the CC view are better appreciated in tomosynthesis than in a 2D CC image.

An even more challenging situation is when the exam consists solely of a tomo MLO. It could be difficult to see asymmetries with only one view, and comparison to 2D prior images would also be challenging. The best clinical performance will likely be seen in protocols that acquire both a tomo CC and MLO image set.

Performing two views uses more radiation dose than one view. However, these doses are commonly accepted in conventional mammography, where two-view mammography is performed to optimize the cancer detection rate. Likewise, two-view tomosynthesis is associated with higher sensitivity along with reduction in recall rates, as compared to single-view tomosynthesis, where sensitivity will suffer.

An alternative approach to acquiring two tomosynthesis views, given a fixed radiation dose, would be to acquire only one tomosynthesis view, but double the dose for that view. This certainly would lower noise and may result in a superior image due to the increased photon statistics. However, better clinical performance has been seen for two-view tomosynthesis than for higher dose single-view tomosynthesis. The Gennaro 2009 study showed that the use of single-view tomo at 2x dose achieved inferior performance, compared to digital mammography, whereas Michell, who used two tomo views at approximately 1x dose each, achieved superior performance.^{29,30}

Benefits of Having Both Tomosynthesis and 2D Images in All Views

There are several reasons why acquiring both a 2D mammography and tomosynthesis image together are useful, especially in screening. It is well known that comparison of current images with prior images is standard mammography practice and critical to perceive subtle changes which may be associated with a cancer. Obtaining a 2D exam along with the tomo exam allows direct comparison of current 2D images with prior 2D images.

The 2D exam is also useful for the rapid detection of calcifications and perception of their distribution. Segmental and clustered calcifications are more easily and quickly appreciated with 2D because they can traverse multiple tomosynthesis slices.

The tomosynthesis portion of the 2D plus tomo exam is also critical in optimizing performance. The tomo image reduces structure overlap, minimizing recalls for overlapped structures and better demonstrates masses and architectural distortions.

Because of the value of having both 2D and tomo views, the original Hologic FDA trials looked at the performance of tomosynthesis when used in combination with 2D. The trial demonstrated superior performance with the addition of tomo, but at the cost of additional radiation

dose to the patient due to the essentially double exposures of both tomo and 2D. Using Hologic's C-View software it is possible to generate a 2D image directly from the tomo dataset, obviating the need for 2D exposures, and providing the clinical benefit of both 2D and tomo at essentially the same radiation dose as a 2D exam alone. Additional information about this process is provided in the following section.

Both the 2D and tomosynthesis images in an exam are valuable. In conclusion:

- The 2D image is useful for comparison to priors
- The 2D image allows for quick reading of microcalcifications
- The tomo image reduces structure overlap and better demonstrates masses
- Using *both* the 2D and tomo in *both* the CC and MLO views maximizes clinical performance
- Using C-View software allows the generation of the 2D images with no additional radiation beyond the tomo exposures

Patient Selection and Management

Most breast imaging centers have multiple digital mammography systems, and it may not be economically feasible to immediately replace every 2D system with tomo-capable units. It is likely that many facilities will implement tomosynthesis in phases, beginning with one or two systems initially, similar to the pattern seen in the transition from analog to digital mammography. During this implementation phase, facilities will need to develop criteria for determining which patients will receive tomo exams, and processes to ensure efficient patient management in a mixed 2D and tomosynthesis environment.

Determining which patients should receive tomo exams is not a straightforward issue and there is not a single solution that will fit every situation. Each facility must consider what is known about the benefits of tomosynthesis and make decisions based on their unique requirements and implementation strategy. Some potential considerations are outlined below.

Use of Tomosynthesis for Screening or Diagnostic Imaging

Tomosynthesis has shown value in a diagnostic evaluation of a symptomatic breast. It also can be used as a screening tool to improve sensitivity and reduce recalls. Therefore, either or both indications are acceptable uses of tomosynthesis. Since diagnostic procedures often take longer than screening exams, more women per day can be accommodated on machines dedicated to screening use. This might be a consideration in situations where a limited number of tomo-capable systems are available.

Use of Tomosynthesis for Women with Dense Breasts

Tomosynthesis has been shown to have value in both fatty and dense breasts, but it has a greater impact for women with dense breasts. Therefore, if a practice does not have enough systems to screen all women, it is reasonable to reserve tomosynthesis for women with dense breasts. However, as tomosynthesis offers a benefit in both fatty and dense breasts, the eventual goal should be to screen all women using tomosynthesis imaging.

Reducing Patient Dose in Tomosynthesis

One area in which extensive research and development efforts have been focused is the creation of a 2D image generated from a tomosynthesis data set. This method provides a 2D image for use during tomosynthesis image review, but does not require an x-ray exposure to generate the 2D image as it is created directly from the tomosynthesis slices. In November 2011, Hologic announced the commercial release and CE mark of its C-View synthesized 2D image reconstruction algorithm that eliminates the need for a conventional 2D mammogram as a component of a tomosynthesis screening procedure.

This approach provides the advantage of reducing the number of exposures, leading to shorter exam times, increased patient comfort due to reduced time under compression and reduced patient dose. This software allows screening with tomosynthesis at the same dose as conventional digital mammography.³²

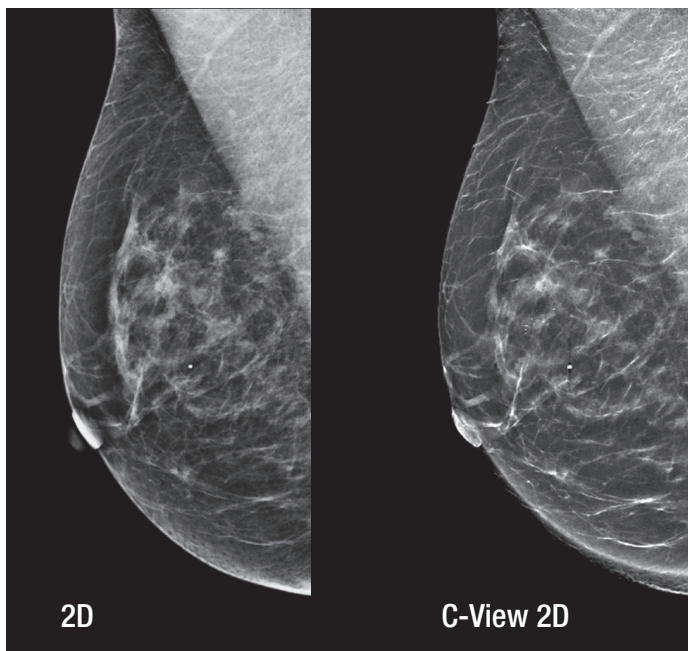
The performance of the generated 2D image has been evaluated in the clinical trial in support of the C-View software FDA submission. The clinical trial demonstrated that:

- Tomosynthesis with C-View 2D images is **superior** to 2D alone **for all breast types**
- Tomosynthesis with C-View 2D images is **superior** to 2D alone in reducing recall rates

Wallace et al. studied the performance of C-View 2D images in a reader study, and using ROC analysis concluded that synthetic 2D mammograms with tomosynthesis allowed similar interpretive performance to standard digital mammography in combination with tomosynthesis and, therefore, may be an acceptable alternative for screening.³³

The performance of C-View software in screening has perhaps been most extensively measured in the Skaane tomosynthesis screening trial. Using tomosynthesis plus C-View 2D images, Skaane reported an increase in cancer detection compared to 2D imaging.³ Most recently, a direct comparison between the performance of tomosynthesis with digital mammography to the performance of tomosynthesis with C-View 2D images found comparable results regarding positive predictive values and cancer detection rates.³⁴

In the Oslo trial, tomosynthesis with C-View 2D images showed comparable cancer detection and positive predictive value as tomo with digital mammography.



C-View images eliminate the need for additional exposures and keep the dose for tomosynthesis exams the same as that of a digital mammography exam.

Tomosynthesis Reading Time

Tomosynthesis involves the generation of considerably more images than standard digital mammography, as each single 2D digital image is now replaced with perhaps 50 or more slices. As a result, the time to perform the evaluation of these images has been a topic of interest. Initial results indicated that the reading time approximately doubled from 49 seconds to 92 seconds for a 4-view bilateral exam.³ As readers become more experienced, it now appears that the increase in reading time using tomosynthesis is becoming smaller. The group from Oslo report that, after reading 2,000 examinations, the tomosynthesis reading time is approximately 60 seconds.³⁵ They conclude that tomosynthesis interpretation time is acceptable for high-volume screening.

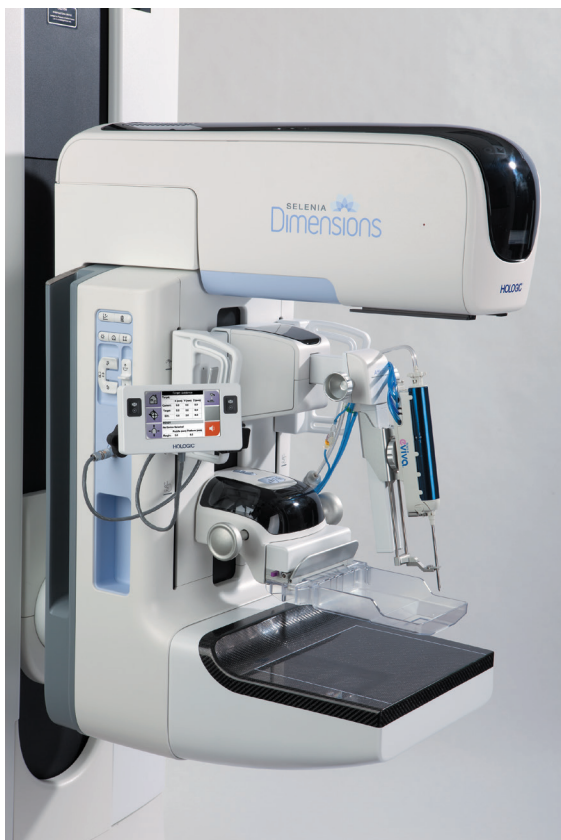Advances in Tomosynthesis

The growing adoption of tomosynthesis in clinical use creates an opportunity for technological evolutions that may be useful in streamlining workflow, improving diagnostic accuracy and expanding clinical applications. Some of the recent advances and ongoing efforts in these areas are discussed in the following sections.

Tomosynthesis-Guided Biopsy

The ultimate diagnosis of a breast cancer lesion is made using biopsy tissue sampling. The ability for tomosynthesis to identify lesions not readily visibly with digital mammography or ultrasound has created a problem – how can a biopsy be performed if a lesion cannot be located using standard biopsy imaging methods? Many lesions found with tomosynthesis can in retrospect be located and biopsied under stereotactic guidance, or biopsied using ultrasound imaging. But subtle lesions sometimes can only be identified using tomosynthesis imaging. This requires that biopsy systems employ imaging and localization using tomosynthesis. The Hologic Selenia Dimensions system offers an interventional add-on device that utilizes tomosynthesis for lesion identification and targeting. Using this device, a single tomo scan is performed and the lesion is targeted and the x,y,z location of the lesion calculated directly from the tomosynthesis image.

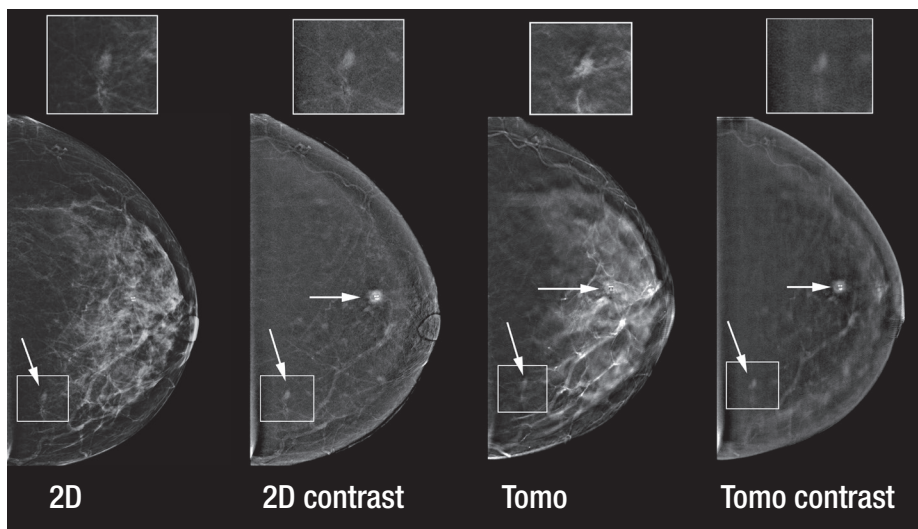
Advantages of this procedure compared to stereotactic biopsy include improved visibility of lesions that are occult in 2D imaging, faster lesion targeting, fewer x-ray exposures, and reduced patient procedure time.



The Affirm™ breast biopsy guidance system used with the Selenia Dimensions system enables tomosynthesis guidance for biopsy procedures.

Contrast Enhanced Breast Imaging

Contrast enhanced breast imaging is a procedure that images the distribution of an iodinated contrast agent using either 2D or tomosynthesis x-ray imaging technologies. This technology is in its early evaluation stage, but may offer some advantages relative to contrast breast MRI in terms of reduced cost, comparable care to patients for whom MRI is contraindicated, and access to patients in areas where MRI systems are not available. Contrast enhanced breast imaging combines functional information from the distribution of the contrast agent and morphological information from the x-ray images. Hologic has received FDA approval and CE mark for a dual modality system, capable of imaging the functional 2D contrast uptake and the morphological tomosynthesis image in rapid sequence, and combining these two image sets into a single fused study. In the fused study, the 2D contrast image can identify potential lesions based on their physiological state which causes increased contrast agent uptake. The standard tomo image can then be overlaid on the 2D contrast image and provide morphological information on the lesion, such as improved visibility of associated spiculations.



CONTRAST IMAGING: This study of 2D and tomosynthesis iodine contrast mammography was acquired under a single compression. The proven cancer in the subareolar breast (horizontal arrow) is not visible on the enhanced 2D mammogram except for the clips placed at biopsy but is easily seen on the 2D and tomosynthesis dual energy contrast images. Contrast imaging led to the detection of an additional cancer in the far medial breast (downward arrow.) The tomosynthesis image shows the irregular shape of the lesion, making it highly likely that the lesion is malignant.

Conclusions

Tomosynthesis is an exciting new technology that is revolutionizing mammography. It has demonstrated value in both screening and diagnostic evaluations. The improvements in clinical performance, compared to 2D mammography, are significant. Multiple peer-reviewed clinical publications report that the use of two-view tomosynthesis in screening offers both improved cancer detection rates and reduced callback rates, compared to 2D alone.

Clinical studies using the Hologic breast tomosynthesis system have demonstrated superior performance in the detection of masses and architectural distortions and equivalent or slightly better performance in the detection of microcalcifications in using 2D plus tomo imaging compared to 2D alone. Acquisition of both the CC and MLO views in 2D and tomo provided statistically significant superior performance compared to 2D alone; however, use of only the MLO tomo with both the 2D CC and MLO views also provided better performance compared to 2D alone – just not as good as acquiring both CC and

MLO tomo. Finally, it was demonstrated that the addition of tomosynthesis to conventional 2D imaging provides improved performance in both fatty and dense breasts, compared to 2D alone, with the performance gain in dense breasts higher than in fatty breasts.

With the use of the C-View generated 2D image, the cancer detection and other clinical benefits of tomosynthesis are available at comparable radiation dose to standard 2D digital imaging and at half the dose of 2D plus 3D imaging.

There is a growing body of evidence that tomosynthesis has the potential to reduce the number of exposures needed for diagnostic imaging and provide other diagnostic benefits including enhanced performance in assessing tumor size and stage and more clearly demonstrating margins and extent of lesions.

Evolving applications in tomosynthesis include contrast enhanced imaging for patients where access to breast MRI is limited or contraindicated, and methods of biopsying lesions under tomosynthesis image guidance.

Glossary

2D	Conventional digital mammography
Breast tomosynthesis	A technology involving limited angle tomography acquisition and reconstruction. Also referred to as digital breast tomosynthesis, DBT, 3D mammography, 3D tomosynthesis, tomosynthesis and tomo.
Callback rate	Same as recall rate. The percentage of women recalled from screening for further assessment. In mammography screening, the majority of recalled cases are false positives.
Combo mode	An imaging mode whereby both a tomosynthesis and 2D FFDM image set are acquired in one breast compression. With the use of C-View, the 2D image is generated from the tomosynthesis scan and does not require additional exposures.
C-View™	2D image generated from the tomosynthesis reconstructions
Recall rate	The percentage of women recalled from screening for further assessment. In mammography screening, the majority of recalled cases are false positives.
ROC	Receiver Operating Characteristics
Sensitivity	The measure of how many cancers are detected.
Specificity	The measure of how many non-cancers are correctly identified.
Synthesized 2D	A method of creating a 2D image from a reconstruction of a tomosynthesis dataset. See C-View.

References

- ¹ Rafferty EA, Park JM, Philpotts LE et al. Assessing radiologist performance using combined digital mammography and breast tomosynthesis compared with digital mammography alone: results of a multicenter, multireader trial. *Radiology Jan*; 266(1): 104-13, 2013.
- ² Gur D, Bandos AI, Rockette HE, et al. Is an ROC-type response truly always better than a binary response in observer performance studies? *Acad Radiol*. (17)5:639-645, 2010.
- ³ Skaane P, Gullien R, Eben EB, et al. Reading time of FFDM and tomosynthesis in a population-based screening program. *Radiological Society of North America annual meeting*, Chicago, IL, 2011.
- ⁴ Skaane P, Bandos AI, Gullien R, Eben EB, et al. Comparison of digital mammography alone and digital mammography plus tomosynthesis in a population-based screening program. *Radiology*, Apr; 267(1):47-56, 2013.
- ⁵ Skaane P, Bandos AI, Gullien R et al. Prospective trial comparing full-field digital mammography (FFDM) versus combined FFDM and tomosynthesis in a population-based screening programme using independent double reading with arbitration. *Eur Radiol* 2013 Aug; 23(8):2061-71.
- ⁶ Ciatto S, Houssami N, Bernardi D, et al. Integration of 3D digital mammography with tomosynthesis for population breast-cancer screening (STORM): a prospective comparison study. *Lancet Oncology*. Jun; 14(7):583-9, 2013.
- ⁷ Haas BM, Kalra V, Geisel J, et al. Comparison of Tomosynthesis Plus Digital Mammography and Digital Mammography Alone for Breast Cancer Screening. *Radiology* 2013 Dec;269(3):694-700. Epub 2013 Jul 30.
- ⁸ Mainiero M, Lourenco A, Barry-Brooks M. Breast Cancer Screening Pre and Post-tomosynthesis: Comparison of Recall Rate, Biopsy Positive Predictive Value, and Cancer Detection Rate. *Radiological Society of North America annual meeting*, Chicago, IL, 2013.
- ⁹ Mitra N, McCarthy AM, Kontos D, et al. Implementing Digital Breast Tomosynthesis (DBT) in a Screening Population: PPV1 as a Measure of Outcome. *Radiological Society of North America annual meeting*, Chicago, IL, 2013.
- ¹⁰ Rose SL, Tidwell AL, Bujnoch LJ, et al. Implementation of breast tomosynthesis in a routine screening practice: an observational study. *AJR Am J Roentgenol*. 2013 Jun; 200(6):1401-8, 2013.
- ¹¹ Rafferty EA, Niklason L. FFDM versus FFDM with tomosynthesis for women with radiologically dense breasts: an enriched retrospective reader study. *Radiological Society of North America annual meeting*, Chicago, IL, 2011.
- ¹² Rafferty EA, Niklason L, Smith A. Comparison of FFDM with breast tomosynthesis to FFDM alone: performance in fatty and dense breasts. *Tomosynthesis Imaging Symposium*, Duke University, 2009.
- ¹³ Philpotts LE, Raghu M, Geisel JL, et al. Tomosynthesis in Breast Cancer Visualization as a Function of Mammographic Density. *Radiological Society of North America annual meeting*, Chicago, IL, 2013.
- ¹⁴ Gandini G, Fonio P, Bergamasco L, et al. Comparative study with digital mammography (DM) combined with digital breast tomosynthesis (DBT) for detection of invasive lobular carcinoma (ILC). *Radiological Society of North America annual meeting*, Chicago, IL, 2013.
- ¹⁵ Berg WA, Blume JD, Cormack JB, et al. Combined screening with ultrasound and mammography vs. mammography alone in women with elevated risk of breast cancer. *JAMA* May 14; 299(18):2151-63, 2008.
- ¹⁶ Zuley ML, Bandos AI, Ganott MA, et al. Digital breast tomosynthesis versus supplemental diagnostic mammographic images for evaluation of non-calcified breast lesions. *Radiology*, Jan; 266(1): 89-95, 2013.
- ¹⁷ Harvey JA, Nicholson BT, Cohen MA. Finding early invasive breast cancers: a practical approach. *Radiology*, July 2008; 248:61-76.
- ¹⁸ Butler RS, Crenshaw J, Kalra V, et al. How tomosynthesis optimizes patient work up, throughput, and resource utilization. *Radiological Society of North America annual meeting*, Chicago, IL, 2013.
- ¹⁹ Savhn T, Andersson I, Chakraborty D, et al. The diagnostic accuracy of dual-view digital mammography, single-view tomosynthesis and a dual-view combination of breast tomosynthesis and digital mammography in a free-response observer performance study. *Radiat Prot Dosimetry*. 139(1-3): 113-117(2010).
- ²⁰ Moon WK, Cho N, Bae Min Sun et al. Value of additional digital breast tomosynthesis combined with digital mammography in a diagnostic setting. *Radiological Society of North America annual meeting*, Chicago, IL, 2013.
- ²¹ Michell M, Iqbal A, Wasan R, et al. A comparison of the accuracy of digital breast tomosynthesis with two dimension digital mammography in measurement of breast tumour size. *Radiological Society of North America annual meeting*, Chicago, IL, 2010.
- ²² Fornvik D, Zackrisson S, Ljunberg O, et al. Breast Tomosynthesis: Accuracy of tumor measurement compared with digital mammography and ultrasonography. *Acta Radiol* 3; 240-247, 2010.
- ²³ Meacock LM, et al. The accuracy of breast cancer size measurement: Digital breast tomosynthesis (DBT vs. 2D digital mammography (DM)). *European College of Radiology annual meeting*, Vienna, Austria, 2010.
- ²⁴ Tagliafico A, Astengo D, Cavagnetto F, et al. One-to-one comparison between digital spot compression view and digital breast tomosynthesis. *Eur Radiol*. Mar;22(3):539-44, 2012.
- ²⁵ Wald NJ, Murphy P, Major P, et al. UKCCCR multicentre randomized controlled trial of one and two view mammography in breast cancer screening. *BMJ* 311:1189-93, 1995.
- ²⁶ Rafferty E, Niklason L, Jameson-Meehan L. Breast tomosynthesis: one view or two? *Radiological Society of North America annual meeting*, Chicago, IL, 2006.
- ²⁷ Beck N, Butler R, Durand M et al. One-View Versus Two-View Tomosynthesis: A Comparison of Breast Cancer Visibility in the Mediolateral Oblique and Craniocaudal Views. *American Roentgen Ray Society annual meeting*, Washington, D.C. April 2013.
- ²⁸ Baker JA, Lo JY. Breast tomosynthesis: state-of-the-art and review of the literature. *Academic Radiology* 18:10. 1298-1310, 2011.
- ²⁹ Michell MJ, Iqbal A, Wasan R, et al. Phase I trial to determine the performance of digital breast tomosynthesis versus two dimension digital and film-screen mammography. *Radiological Society of North America annual meeting*, Chicago, IL, 2010.
- ³⁰ Gennaro G, Toledano A, di Maggio C, et al. Digital breast tomosynthesis versus digital mammography: a clinical performance study. *Eur Radiol* 20:1545-1553, 2009.
- ³¹ Wallis MG, Moa E, Zanca F, et al. Two-view and single-view tomosynthesis versus full-field digital mammography: high-resolution x-ray imaging observer study. *Radiology*, Mar;262(3):788-96, 2012.
- ³² <http://www.fda.gov/downloads/AdvisoryCommittees/CommitteesMeetingMaterials/MedicalDevices/MedicalDevicesAdvisoryCommittee/RadiologicalDevicesPanel/UCM325901.pdf>.
- ³³ Wallace LP, Rathfon GY, Ganott MA et al. Diagnostic Accuracy of Combination Synthetic Mammograms with Tomosynthesis vs. Combination FFDM with Tomosynthesis. *Radiological Society of North America annual meeting*, Chicago, IL, 2013.
- ³⁴ Krafer M, Ekseth U, Haakenaasen U et al. Implementation of Synthesized 2D Plus Tomosynthesis Images in Breast Cancer Screening: Comparison of Performance Levels with Full Field Digital Mammography Plus Tomosynthesis in a Population-based Screening Program. *Radiological Society of North America annual meeting*, Chicago, IL, 2013.
- ³⁵ Ekseth U, Jahr G, Izadi M, et al. Trends in Time to Interpretation of Tomosynthesis Based Screening Examinations with Increasing Experience. *Radiological Society of North America annual meeting*, Chicago, IL, 2013.

Hologic, Inc.

35 Crosby Drive
Bedford, MA 01730 USA
T: 781.999.7300

www.hologic.com
womenshealth@hologic.com