HITACHI
Inspire the Next

Clinical Report

Tools to evaluate fetal cardiac function

- Fetal heart rate, fetal arrhythmia, systolic and diastolic function -

Evaluate fetal heart function

It is reported that approximately 1% of infants are suffering CHD (Congenital Heart Defects), however, early detection of CHD improves the survival rate of those patients by 50% or more. So, the importance of fetal heart evaluation like Doppler measurement of uterine artery (UA) and middle cerebral artery (MCA) is getting higher.
However, as ultrasound technology advances recently, direct observation of fetal cardiac function has got possible.

Morphological observation
- B mode resolution
- *e*FLOW

Fetal heart functional examination
- AutoFHR (①)
- Dual Gate Doppler (②)
- TDI-PW (③)
- 2DTT

Diseases follow up
- STIC&VSI
- ConvexCW (④)

① AutoFHR

●Check-up of fetal heart rate

Fetal heart rate is automatically measured from B mode image with tracking of heart movement. Compared to conventional Doppler mode and M mode, safer and more objective measurement is possible. Further more, it is possible to observe fetal growth from very early stage because this function is available on a transvaginal probe as well.

Measurement ROI setting by user

↓

Tracking process of fetal heart

↓

Draw heart beart frequency graph from image of ROI. Extract few beats (ex.3 beats) and estimate heart rate.

↓

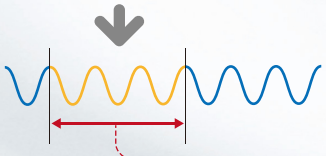

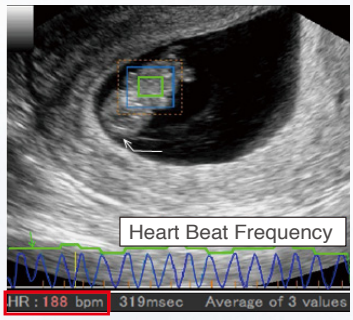

●Use case example

- Fetal heart rate measurement (required for risk calculation in FMF* guideline)
- Heart beat check in infertility treatment
- Relation between heart rate and miscarriage

* FMF :Fetal Medicine Foundation

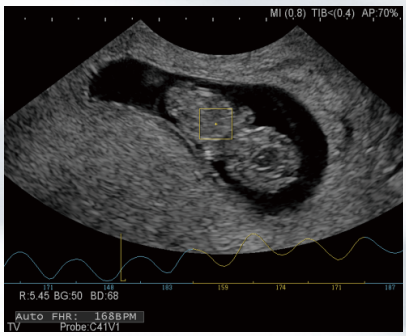

9w6d (Trans vaginal approach)

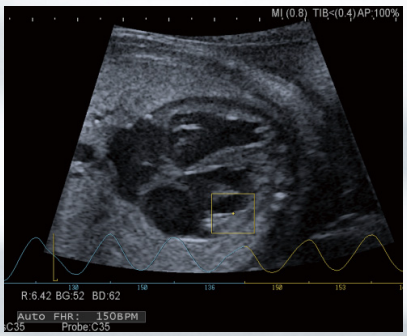

32w6d (Trans abdominal approach)

AutoFHR is an automated heart rate measurement which can be applied at a very low gestational age by using the B mode image only, with low acoustic power based on ALARA principle.
Because of its simple operation, AutoFHR is fast and very easy to understand for both user and patient alike. It is expected that AutoFHR of Hitachi will become a standard measurement method.

Masahiko Nakata, M.D.,Ph.D.
Professor
Department of Obstetrics and Gynecology
School of Medicine
Faculty of Medicine, Toho University

ALOKA
illuminate the change

❷ Dual Gate Doppler

●Observe fetal arrhythmia, diastolic function(right heart / left heart), cardiac output from both ventricles

Dual Gate Doppler which can detect 2 sample points simultaneously can detect not only blood flow but also be used in combination with tissue Doppler. It realizes E/e' which is one of left ventricle diastolic function index, and measurement of inflow and outflow, etc. in the single beat.

Advantage to measure by 2 sample points

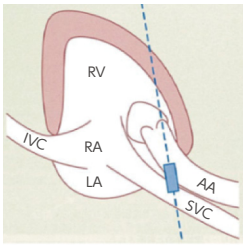

〈An example by coventional Doppler method〉

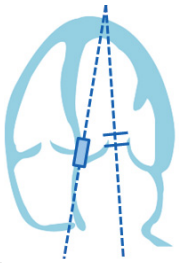

〈Dual Gate Doppler〉

❶Possible to detect Doppler signal of separate points
❷Possible to measure 2 points in same phase simultaneously
❸Expected to be used for RA and RV related measurements
❹Combined evaluation of PW(Pulsed-wave Doppler) and TDI (Tissue Doppler Imaging) is possible

Fetal arrhythmia observation

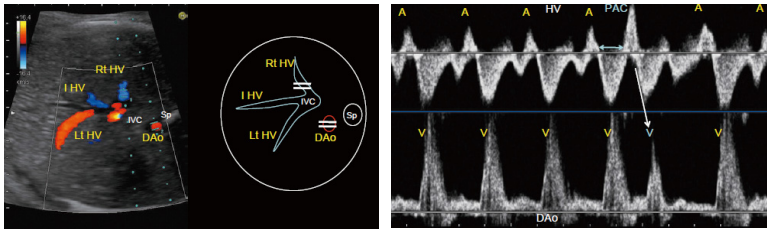

Possible to record hepatic vein and descending aorta which are isolated from each other. Hepatic vein can be measured in abdominal cross section plane and possible to image descending aorta in same plane simultaneously. It is possible to check atrial contraction from A-wave of hepatic vein, and ventricular contraction from V-wave of descending aorta. Rhythm between chambers can be observed in longitudinal relation of PW display.

※Practice for Evaluating of Fetal Arrhythmias by Simultaneous Recordings of Pulsed Wave Doppler Signals in Hepatic Vein and Descending Aorta Using Dual Doppler ; MEDIX
Takashi Kaji, Kazuhisa Maeda, Masanori Suto, Soichiro Nakayama, Miki Sato, Minoru Irahara

Observe left heart diastolic function

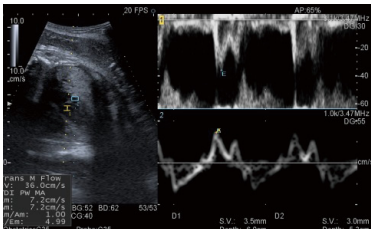

PW/TDI : E/e' calculation

'PW/TDI' can calculate E/e' in the same cardiac phase. E/e' of fetus is reported to be closely related to diseases.

❸ TDI-PW

●Observe diastolic and systolic function from velocity of myocardium

TDI(Tissue Doppler Imaging) displays Doppler signal from heart (tissue) selectively, and able to make quantitative evaluation of myocardial movement velocity and direction.

TDI-PW can avoid color noise from fetal movement, and display TDI by one click without color display.

MPI(Myocardial Performance Index) measurement by TDI-PW

❹ Convex CW

●Observe regurgitation and high velocity blood flow of stenosis area

Possible to measure high velocity blood flow, which is difficult to evaluate by PW Doppler, by a convex transducer. No need to change to a sector transducer.

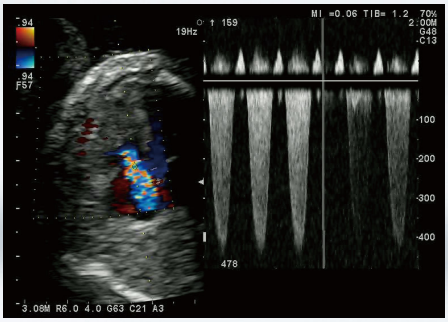

TR(Tricuspid Regurgitation)

Hitachi Aloka Medical, Ltd.

6-22-1, Mure, Mitaka-shi, Tokyo, 181-8622 Japan Telephone: +81 422 45 6049 Facsimile: +81 422 45 4058 www.hitachi-aloka.com

MC2015(200)TY